

## CASO CLÍNICO/CASE REPORT

**Distal Involvement and Subsarcolemmal Minicore-Like Areas in a Case of *POGLUT1*-Associated Myopathy****Miopatia por Mutação no Gene *POGLUT1*: Envolvimento da Musculatura Distal e Áreas *Minicore-Like* Subsarcolémicas**

✉ Maria João Malaquias <sup>1,\*</sup>, Miguel Mendonça Pinto <sup>2</sup>, Eduarda Pinto <sup>3</sup>, Jorge Pinto Basto <sup>4</sup>, Márcio Cardoso <sup>5</sup>,

✉ Manuel M Pires <sup>2</sup>, ✉ Ricardo Taipa <sup>2</sup>, João Chaves <sup>1</sup>

1-Neurology Department / Centro Hospitalar Universitário do Porto, Porto, Portugal

2-Neuropathology Unit / Centro Hospitalar Universitário do Porto, Porto, Portugal

3-Neuroradiology Department / Centro Hospitalar Universitário do Porto, Porto, Portugal

4-CGC Genetics, Porto, Portugal / CGC Genetics, Porto, Portugal

5-Neurophysiology Department / Centro Hospitalar Universitário do Porto, Porto, Portugal

DOI: <https://doi.org/10.46531/sinapse/CC/220035/2022>

**Abstract**

Pathogenic biallelic variants in *POGLUT1* were linked to limb-girdle muscular dystrophy R21 (LGMD R21), a new type of LGMD featuring pelvic and shoulder girdle weakness, variable age of onset, slowly progressive course, and “inside-to-outside” fatty degeneration pattern in muscle magnetic resonance imaging (MRI). We describe a 54-year-old female with an infantile-onset, slowly progressive, pelvic-girdle myopathy, who later, after the age of 50, has developed finger flexors weakness. Muscle MRI revealed advanced fatty degeneration of the deeper thigh muscles, partially sparing the superficial regions (“inside-to-outside” pattern). Muscle biopsy showed pronounced myopathic features and internal structure disorganization, resembling minicore-like areas. Whole exome sequencing analysis identified a pathogenic homozygous variant in *POGLUT1*. By describing minicore-like areas and unique finger flexion involvement, in the absence of proximal upper limbs weakness, our case expands the histological and clinical spectrum of *POGLUT1*-associated myopathies. It further reinforces “inside-to-outside” muscle MRI pattern as a core diagnostic feature.

**Resumo**

Mutações no *POGLUT1* foram associadas à distrofia muscular das cinturas recessiva 21 (DMC R21), um novo tipo de DMC caracterizada por fraqueza das cinturas escapular e pélvica, idade de início variável, evolução lenta e degeneração lipídica dos músculos profundos da coxa na ressonância magnética (RM) muscular. Apresentamos uma mulher de 54 anos, com miopatia da cintura pélvica, de início infantil, que após os 50 anos, desenvolve fraqueza da flexão dos dedos das mãos. A RM muscular mostrou degeneração lipídica dos músculos profundos da coxa, poupando as regiões superficiais (padrão “inside-to-outside”). A biópsia muscular revelou alterações da estrutura interna, sugerindo áreas *minicore-like*. A sequenciação do exoma identificou uma variante patogénica, em homozigotia, no *POGLUT1*. O presente caso alarga o espetro fenotípico do gene *POGLUT1*, ao descrever estruturas *minicore-like* e o envolvimento dos flexores dos dedos das mãos, na ausência de fraqueza proximal. Adicionalmente, reforça o valor diagnóstico do padrão “inside-to-outside” na RM muscular.

**Informações/Informations:**

Caso Clínico, publicado em Sinapse, Volume 22, Número 2, abril-junho 2022. Versão eletrónica em [www.sinapse.pt](http://www.sinapse.pt); Case Report, published in Sinapse, Volume 22, Number 2, April-June 2022. Electronic version in [www.sinapse.pt](http://www.sinapse.pt)  
© Autor (es) (ou seu (s) empregador (es)) e Sinapse 2022. Reutilização permitida de acordo com CC BY-NC. Nenhuma reutilização comercial.  
© Author(s) (or their employer(s)) and Sinapse 2022. Re-use permitted under CC BY-NC. No commercial re-use.

**Keywords:**

Glucosyltransferases/genetics; Muscular Dystrophies/genetics; Mutation.

**Palavras-chave:**

Distrofias Musculares/genética; Glucosiltransferases/genética; Mutação.

**\*Autor Correspondente /****Corresponding Author:**

Maria João Malaquias  
Largo do Prof. Abel Salazar,  
4099-001 Porto, Portugal  
[mariajcmalaquias@gmail.com](mailto:mariajcmalaquias@gmail.com)

**Recebido / Received:** 2022-04-26

**Aceite / Accepted:** 2022-06-13

**Publicado / Published:** 2022-06-30

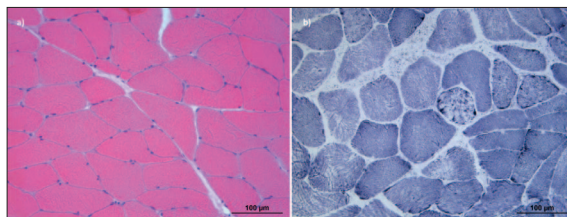
## Introduction

*POGLUT1* mutations (OMIM\* 615618), primarily described in a dominant pure pigmentation disorder named Dowling-Degos disease, were recently linked to a new type of limb-girdle muscular dystrophy (LGMD type R21) (OMIM# 617232), by Servián-Morilla et al (2016, 2020).<sup>1,2</sup> Fifteen patients have been reported with this phenotype, which includes weakness involving the upper and lower proximal limbs, variable age of onset, and slowly progressive course, occasionally with mild respiratory involvement, but leading invariably to wheelchair confinement. Additionally, a “inside-to-outside” muscle magnetic resonance imaging (MRI) pattern, and alpha-dystroglycan hypoglycosylation in muscle biopsy are depicted as supporting diagnostic features.<sup>2</sup> Disease-causing variants in *POGLUT1*, encoding the protein O-glycosyltransferase I, lead to disruption of the Notch signaling pathway, involved in the maintenance of muscle-specific adult stem cell homeostasis.<sup>1</sup>

*POGLUT1*-associated myopathies are sparsely described in literature. Our case corroborates some known phenotypic features and add new ones.

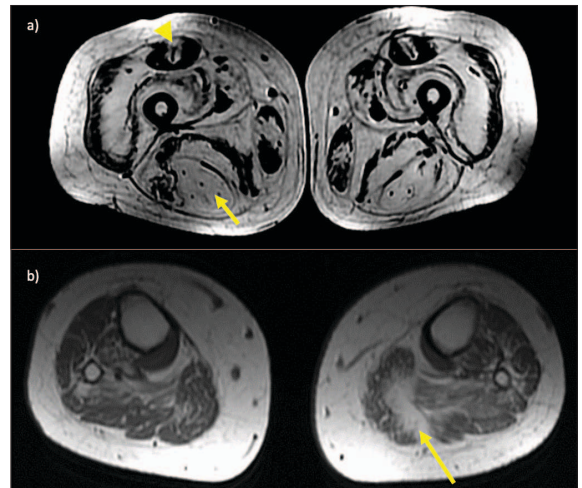
## Case Report

The 54-year-old female patient, born from healthy consanguineous parents, had normal birth history and psychomotor development. After the age of 10, she began to notice difficulties in climbing stairs, and at 16 years old, she underwent scoliosis correction surgery. Muscle weakness slowly worsened, so that she retired in mid-30s and started using a cane at 45 years. A deltoid muscle biopsy, performed at 49 years revealed mild myopathic features (Fig. 1). At the age of 50, weakness progressed to the hands and the patient was wheelchair-bound most of the time. Moreover, since 51 years old, she complains of tingly and numb feet and hands, and transitory, cold-induced “red spots” have appeared on her thighs. She has a past history of severe childhood-



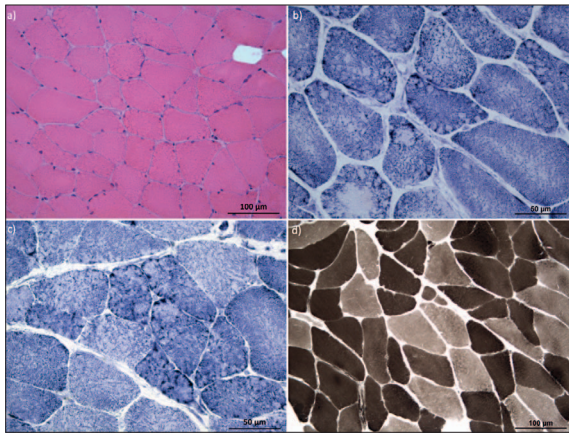
**Figure 1.** Deltoid muscle biopsy performed at 49 years. a) H&E showing increased variability of fiber diameter and occasional round atrophic fibers, but conserved myofibrillar internal structure. 2) Rare fibers with disorganization of NADH enzymatic activity with lobular and trabecular appearance.

onset myopia. First neurologic examination at 53 years included scoliosis, severe pelvic-girdle weakness (MRC score of 2/5), reduced strength in fingers flexion, at distal interphalangeal joints (MRC score of 4/5), with finger extensors and intrinsic hand muscles relatively spared, and dysesthesia to pinprick sensation in stocking-and-glove distribution. Proximal upper limbs (UL) weakness (including deltoid weakness), foot dorsiflexor weakness, scapular winging, joint contractures, *pes cavus*, arched palate, and facial or bulbar muscle weakness were not noticed. General examination revealed areas of livedo reticularis in the lower limbs (LL) and Raynaud’s phenomenon. Serum creatine kinase level was within normal range (167 U/L), and further laboratorial investigation, including autoimmune/paraneoplastic, metabolic and infectious workup, was all negative or normal. Cardiac examination revealed moderate to severe aortic regurgitation, excluding structural cardiopathy and arrhythmia. Electromyography showed myopathic pattern (small polyphasic potentials, without abnormal spontaneous activity) in quadriceps, iliopsoas and flexor pollicis longus (FPL), but not in the extensor digitorum and interossei hand muscles, or in the proximal UL and distal LL muscles. Nerve conduction studies (NCS) were normal. No white matter abnormalities were seen on brain MRI. Muscle MRI of LL (Fig. 2) showed



**Figure 2.** Muscle MRI of lower limbs performed at 54 years old. a) Axial T1-weighted images show severe fatty degeneration of all hip and thigh muscles. In the thigh muscles, a pattern of degeneration “from inside to outside” can be depicted, with the deeper areas of the muscles more affected than the superficial ones (except rectus femoris, where fatty infiltration is more prominent at central regions, arrowhead); semitendinosus is diffusely involved (arrow). b) The leg muscles are less severely affected than the hip and thigh muscles. At the calf level, the pattern of fatty degeneration “from inside to outside” is seen in the gastrocnemius on the left (arrow).

advanced fatty degeneration of the anterior and posterior compartments of the thigh muscles, partially sparing the superficial regions (“inside-to-outside” pattern) (Fig. 2.a). The fatty replacement in the leg muscles was asymmetrical and less severe than the thigh muscles (Fig. 2.b). A subsequent quadriceps muscle biopsy (Fig. 3) showed more pronounced myopathic features with round atrophic fibers and focal areas of endomysial fibrosis (Fig. 3.a). Histochemical studies revealed numerous fibers with multiple small subsarcolemmal areas with NADH and SDH activity reduction, resembling minicore-like areas (Fig. 3.b). Other less frequent patterns of internal structure disorganization were also found, either central core-like areas or lobulated fibers (Fig. 3.c), but no true core/minicore areas were demonstrated on ultrastructural studies. These findings were inapparent in ATPase staining (Fig. 3.d). Alpha-dystroglycan staining was not performed. Whole exome sequencing analysis identified a homozygous variant in *POGLUT1* (NM\_152305.3:c.292C>T p.(Arg98Trp)), previously reported to cause LGMD R21 in three patients of a Bulgarian family.<sup>2</sup>



**Figure 3.** Quadriceps muscle biopsy performed at 54 years old. a) H&E stain showing scattered atrophic fibers, mild and focal endomysial fibrosis and multiple small circular areas of myofibrillar disorganization. b) Multiple fibers exhibiting subsarcolemmal round areas of NADH enzymatic activity reduction (minicore-like areas) and other showing irregular central or eccentric larger core-like areas. c) NADH revealing areas with lobulated fibers. d) Minicore-like structures were inapparent at ATPase 4,35 stain. No fiber type predominance is observed.

## Discussion

In our patient, finger flexors were the most prominent affected UL muscles, which is phenotypically different from the typical limb-girdle myopathy (LGM) previously described in *POGLUT1* patients by Servián-Morilla et al.<sup>2</sup> In their serie of patients, distal UL weakness was noticed in one case, associated with severe proximal UL

weakness, and the only patient without shoulder-girdle myopathy had a short disease duration,<sup>2</sup> contrasting to the long-standing course of our patient. LGMs can involve distal muscles, frequently the foot dorsiflexor and finger extensor muscles, at onset or more often during the disease course. Finger flexor involvement (in the absence of finger extensors and intrinsic hand muscles weakness) is rarer and usually associated with sporadic inclusion-body myositis. However, finger flexor weakness can also be found in some cases of genetic myopathies caused by *ACTA1*, *CRYAB*, *DMD*, *DYSF*, *FLNC*, *GAA*, *GNE*, *HNRNPDL*, *LAMA2*, *MYH7*, and *VCP* mutations.<sup>3</sup> We now add *POGLUT1* mutations to this list. It is also noteworthy in needle EMG of the present case, the FLP showed myopathic changes, and the intrinsic hand muscles were preserved, and therefore the finger flexor weakness is not due to associated neuropathy. Furthermore, variants of uncertain significance (VOUS) in genes associated with classical distal myopathies,<sup>4</sup> which could possibly partially contribute to the phenotype, were not found in WES.

Concerning the sensory involvement, the patient presented both positive (paresthesia, dysesthesia) and negative (numbness) clinical signs and the NCS did not identify large nerve fiber involvement. Although further tests were not performed (somatic and autonomic functional tests or quantification of intraepidermal nerve fiber density), we suspect of small fibers neuropathy, for which main acquired (autoimmune, metabolic, infectious and toxic) and genetic (no variants with possible association were found in WES) etiologies were excluded. The cutaneous manifestations observed in our patient comprised Raynaud’s phenomenon and livedo reticularis, and thus were distinct from the pigmentation dermatosis of Dowling-Degos disease. While it is well recognized that Raynaud’s syndrome and livedo reticularis in a middle-age woman can have an idiopathic nature, one can question if this, as well as the other comorbidities presented (valvulopathy, myopia and small fibers neuropathy) are due to *POGLUT1* deficiency in other tissues, as the Notch signaling pathway was associated with other organs homeostasis, such as the heart, skin, vasculature and nerves.<sup>5</sup> In this regard, it is also important to underline that, despite the presence of scoliosis, aortic regurgitation and severe myopia, other Marfan syndrome features were absent in our patient, and WES analysis was negative for VOUS in the *FBNI* gene.

Both muscle biopsies showed morphological changes similar to the literature descriptions, regarding mild myopathic features in unaffected muscles such as the

deltoid muscle, and more severe myopathic or even dystrophic characteristics in weakened muscles such as the quadriceps.<sup>1,2</sup> Furthermore, we observed additional internal structure changes, the most distinguished being the subsarcolemmal minicore-like areas. Nevertheless, true minicores could not be documented on ultrastructural studies. In fact, multi-minicore myopathies are clinical and genetically heterogeneous disorders whose severity and congenital onset differs from our patient's course.<sup>6</sup> Although a similar histoenzymatic pattern has recently been described in *ACTN2*-related myopathy,<sup>7</sup> no VOUS were found in this or any multi-minicore myopathies genes.<sup>6</sup> Irregular core-like areas and lobulated fibers, such as observed in this patient, are unspecific and can be observed across the muscle dystrophies spectrum, with the latter having already been reported in *POGLUT1*-associated myopathies.<sup>1,2</sup>

Proximal LL MRI findings described here resemble the cases previously reported.<sup>1,2</sup> Notably, our patient exhibit an unusual asymmetrical involvement of the gastrocnemius.

In summary, this report highlights a patient with a pathogenic *POGLUT1* mutation as the cause of an infantile-onset LGM, with later developmental of unique finger flexion involvement, in the absence of proximal UL weakness, and minicore-like structures in muscle biopsy. Our study expands the clinical and histological spectrum of *POGLUT1*-associated myopathies and further reinforces "inside-to-outside" muscle MRI pattern as a core diagnostic feature, even in advanced stages. ■

#### Contributorship Statement / Declaração de Contribuição

MJM and MMP: Conception, organization, design, execution, writing of the first draft and final approval.

EP: Design, execution, review and final approval.

JPB, MC and MMP: Execution, review and final approval.

RT and JC: Conception, organization, review and final approval.

#### Responsabilidades Éticas

Conflitos de Interesse: Os autores declaram a inexistência de conflitos de interesse na realização do presente trabalho.

Fontes de Financiamento: Não existiram fontes externas de financiamento para a realização deste artigo.

Confidencialidade dos Dados: Os autores declaram ter seguido os protocolos da sua instituição acerca da publicação dos dados de doentes.

Consentimento: Consentimento do doente para publicação obtido.

Proveniência e Revisão por Pares: Não comissionado; revisão externa por pares.

#### Ethical Disclosures

Conflicts of Interest: The authors have no conflicts of interest to declare.

Financing Support: This work has not received any contribution, grant or scholarship.

Confidentiality of Data: The authors declare that they have followed the protocols of their work center on the publication of data from patients.

Patient Consent: Consent for publication was obtained.

Provenance and Peer Review: Not commissioned; externally peer reviewed.

#### References / Referências

1. Servián-Morilla E, Takeuchi H, Lee TV, Clarimon J, Mavillard F, Area-Gómez E, et al. A *POGLUT1* mutation causes a muscular dystrophy with reduced Notch signaling and satellite cell loss. *EMBO Mol Med*. 2016;8:1289-309. doi:10.15252/emmm.201505815
2. Servián-Morilla E, Cabrera-Serrano M, Johnson K, Pandey A, Ito A, Rivas E, et al. *POGLUT1* biallelic mutations cause myopathy with reduced satellite cells, -dystroglycan glycosylation and a distinctive radiological pattern. *Acta Neuropathol*. 2020;139:565-82. doi:10.1007/s00401-019-02117-6
3. Nicolau S, Liewluck T, Milone M. Myopathies with finger flexor weakness: Not only inclusion-body myositis. *Muscle Nerve*. 2020;62:445-54. doi: 10.1002/mus.26914
4. Milone M, Liewluck T. The unfolding spectrum of inherited distal myopathies. *Muscle Nerve*. 2019;59:283-94. doi: 10.1002/mus.26332
5. Siebel C, Lendahl U. Notch Signaling in Development, Tissue Homeostasis, and Disease. *Physiol Rev*. 2017;97:1235-94. doi:10.1152/physrev.00005.2017
6. Ogasawara M, Nishino I. A review of core myopathy: central core disease, multiminicore disease, dusty core disease, and core-rod myopathy. *Neuromuscul Disord*. 2021;31:968-77. doi: 10.1016/j.nmd.2021.08.015
7. Lornage X, Romero NB, Grosogeat CA, Malfatti E, Donkervoort S, Marchetti MM, et al. *ACTN2* mutations cause "Multiple structured Core Disease" (MsCD). *Acta Neuropathol*. 2019;137:501-19. doi: 10.1007/s00401-019-01963-8